



# Treatment of *Pneumocystis jirovecii* Pneumonia with Caspofungin and Clindamycin: An HIV Patient and Literature Review

## *Pneumocystis jirovecii* Pnömonisi Tedavisinde Caspofungin ve Klindamisin: Bir HIV Olgusu ve Literatürün Gözden Geçirilmesi

Gül Ruhsar YILMAZ<sup>1</sup>([iD](#)), Onur KAYA<sup>1</sup>([iD](#)), Ahmet Çağkan İNKAYA<sup>2</sup>([iD](#)), Onur ÜNAL<sup>1</sup>([iD](#)), Esra NURLU TEMEL<sup>1</sup>([iD](#)), Füsün Zeynep AKÇAM<sup>1</sup>([iD](#)), Emel SESLİ ÇETİN<sup>3</sup>([iD](#)), Barış OTLU<sup>4</sup>([iD](#)), Serhat ÜNAL<sup>2</sup>([iD](#))

<sup>1</sup> Department of Infectious Diseases and Clinical Microbiology, Süleyman Demirel University Faculty of Medicine, Isparta, Türkiye

<sup>2</sup> Department of Infectious Diseases and Clinical Microbiology, Hacettepe University Faculty of Medicine, Ankara, Türkiye

<sup>3</sup> Department of Medical Microbiology, Süleyman Demirel University Faculty of Medicine, Isparta, Türkiye

<sup>4</sup> Department of Medical Microbiology, İnönü University Faculty of Medicine, Malatya, Türkiye

**Cite this article as:** Yılmaz GR, Kaya O, İnkaya AÇ, Ünal O, Nurlu Temel E, Akçam FZ, et al. Treatment of *Pneumocystis jirovecii* pneumonia with caspofungin and clindamycin: An HIV patient and literature review. FLORA 2024;29(1):139-144.

### ABSTRACT

The first-line treatment for *Pneumocystis jirovecii* pneumonia (PCP) is trimethoprim-sulfamethoxazole (TMP-SMZ). However, some cases require alternative agents due to the side effects of TMP-SMZ. Treatment with TMP-SMZ was initiated in an HIV-positive patient with microbiologically confirmed PCP, who presented with acute renal failure on admission. On the third day of treatment, TMP-SMZ was discontinued due to worsening renal function. Subsequently, clindamycin was initiated in combination with caspofungin. Although caspofungin-based therapies were shown to be effective against *Pneumocystis* in animal models, clinical experience in humans is limited. The patient was treated successfully with clindamycin combined with caspofungin.

**Key Words:** *Pneumocystis jirovecii*; Clindamycin; Caspofungin



## ÖZ

***Pneumocystis jirovecii* Pnömonisi Tedavisinde Kaspofungin ve Klindamisin: Bir HIV Olgusu ve Literatürün Gözden Geçirilmesi**

Gül Ruhsar YILMAZ<sup>1</sup>, Onur KAYA<sup>1</sup>, Ahmet Çağkan İNKAYA<sup>2</sup>, Onur ÜNAL<sup>1</sup>, Esra NURLU TEMEL<sup>1</sup>, Füsün Zeynep AKÇAM<sup>1</sup>, Emel SESLİ ÇETİN<sup>3</sup>, Barış OTLU<sup>4</sup>, Serhat ÜNAL<sup>2</sup>

<sup>1</sup> Süleyman Demirel Üniversitesi Tıp Fakültesi, Enfeksiyon Hastalıkları ve Klinik Mikrobiyoloji Anabilim Dalı, Isparta, Türkiye

<sup>2</sup> Hacettepe Üniversitesi Tıp Fakültesi, Enfeksiyon Hastalıkları ve Klinik Mikrobiyoloji Anabilim Dalı, Ankara, Türkiye

<sup>3</sup> Süleyman Demirel Üniversitesi Tıp Fakültesi, Tıbbi Mikrobiyoloji Anabilim Dalı, Isparta, Türkiye

<sup>4</sup> İnönü Üniversitesi Tıp Fakültesi, Tıbbi Mikrobiyoloji Anabilim Dalı, Malatya, Türkiye

*Pneumocystis jirovecii* pnömonisi (PCP)'nin tedavisinde ilk seçenek antimikrobiyal trimetoprim-sülfametoksazoldür (TMP-SMZ). Ancak olguların bir kısmında TMP/SMZ'nin yan etkileri nedeniyle alternatif ajanların kullanımı gerekmektedir. Başvurusunda akut renal yetmezliği olan ve mikrobiyolojik olarak doğrulanmış PCP tanılı HIV pozitif olguya TMP-SMZ tedavisi başlandı. Tedavinin üçüncü gününde böbrek fonksiyonlarında kötüleşme olması nedeniyle TMP-SMZ kesildi. Kaspofungin bazlı tedavilerin hayvan modellerinde *Pneumocystis*'e karşı etkili olduğu gösterilmiş olsa da insanlarda klinik deneyim sınırlıdır. Sunulan olgu kaspofungin ve klindamisin kombinasyonu ile başarılı şekilde tedavi edilmiştir.

**Anahtar Kelimeler:** *Pneumocystis jirovecii*; Klindamisin; Kaspofungin

**INTRODUCTION**

*Pneumocystis jirovecii* is a known cause of pneumonia in HIV-positive patients with low CD4 counts<sup>[1,2]</sup>. Trimethoprim-sulfamethoxazole (TMP-SMZ) is used for the first-line treatment and prophylaxis in these cases<sup>[1,3-5]</sup>. However, due to side effects, TMP-SMZ may not be used in some patients with *P. jirovecii* pneumonia (PCP), and alternative agents such as primaquine and clindamycin or atovaquone are recommended in the guidelines for opportunistic infections in HIV<sup>[1,5]</sup>. Although caspofungin-based therapies were shown to be effective against *Pneumocystis* in animal models, clinical experience in humans is limited<sup>[6-9]</sup>. In this article, we present a patient who could not tolerate TMP-SMZ due to hematological and renal side effects and was treated successfully with clindamycin combined with caspofungin.

**CASE REPORT**

A 54-year-old male patient presented with complaints of weakness, loss of appetite, chills, and night sweats over the past month. He reported a weight loss of five kg during this period. The patient tested positive for anti-HIV and was subsequently admitted to the hospital.

His vital signs were within the normal range, as follows: body temperature: 36.5°C, pulse rate: 90/min, respiratory rate: 22/min, and blood pressure: 100/70 mmHg. Tenderness was present throughout the abdomen and bilateral inguinal lymphadenopathy of 2 cm was identified during the physical examination. Laboratory results were as follows: Hb: 8.2 g/dL, WBC: 4100/mm<sup>3</sup> (84.2% neutrophils, 7% lymphocytes), platelet count: 244.000/μL, BUN: 62 mg/dL, creatinine: 2.95 mg/dL, LDH: 271.4 U/L, AST: 27.3 U/L, ALT: 10.4 U/L, HIV-RNA: 841000 IU/mL, CD4: 160/mm<sup>3</sup>, CRP: 28.3 mg/L (0-5), and procalcitonin 2.3 ng/mL. Chest radiography was normal. TMP-SMZ was initiated for PCP prophylaxis. Subsequently, the dose of TMP-SMZ was escalated to a therapeutic level following the identification of bilateral ground-glass opacities on high-resolution CT of the chest (Figure 1).

Numerous millimetric lymph nodes are noted in the mediastinum, they have not reached pathological dimensions. Widespread centrilobular nodular appearances with ground-glass opacities are observed, most prominently in the apical segment of the right upper lobe of both lung parenchymal areas.

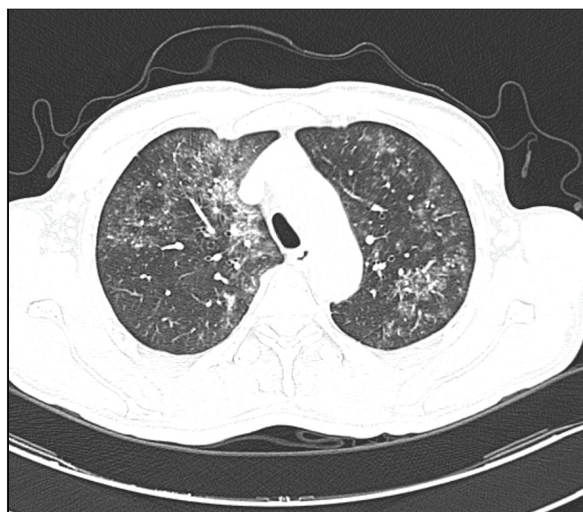


Figure 1. High-resolution CT scans of the chest.

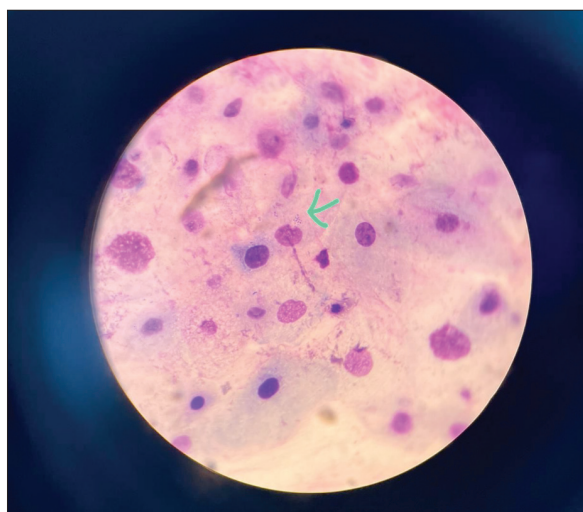


Figure 2. Giemsa staining (x 1000) of *P. jirovecii* cyst.

On the second day of hospitalization, the patient experienced dyspnea and tachypnea. His oxygen saturation level was measured at 84% and blood gas analysis revealed the following results: pH: 7.37, PaCO<sub>2</sub>: 31.4 mmHg, and PaO<sub>2</sub>: 50.3 mmHg. Oxygen treatment via nasal cannula at a rate of 5-6 L/min was initiated and prednisolone 2 x 40 mg was prescribed. TMP-SMZ was discontinued due to a decline in renal function (creatinine: 3.16 mg/dL) on the third day of therapy. The treatment was switched to clindamycin 3 x 600 mg IV and caspofungin at a loading dose of 70 mg followed by a maintenance dose of 50 mg IV.

A *P. jirovecii* cyst was identified on Giemsa staining of the sputum sample and the polymerase chain reaction test was positive.

On the eight day of caspofungin and clindamycin treatment, the patient's oxygen requirement decreased to 3 L/min. Anti-retroviral therapy was postponed until the exclusion of tuberculosis. Bictegravir/emtricitabine/tenofovir alafenamide was initiated as antiretroviral therapy. On the thirteenth day of receiving caspofungin and clindamycin, the patient no longer required oxygen therapy. Their creatinine level steadily decreased and was measured at 0.9 mg/dL on the twelfth day of hospitalization. Treatment was discontinued on the 28<sup>th</sup> day. TMP-SMZ was prescribed for secondary prophylaxis. On the seventh day of TMP-SMZ therapy, the patient's WBC count decreased from 4900 to 3300/mm<sup>3</sup>, the platelet count dropped from 20.000/μL to 9000/μL, and hemoglobin (Hb) levels decreased from 9.7 to 7.3 g/dL. Consequently, secondary prophylaxis was switched to clindamycin at a dose of 1 x 600 mg.

## DISCUSSION

Despite advances in antiretroviral therapy, PCP is still one of the major causes of mortality in people living with HIV<sup>[10]</sup>. The mortality rate among confirmed cases of PCP has been reported to be approximately 10%<sup>[11]</sup>.

TMP-SMZ is the first choice for PCP prophylaxis and treatment, but dihydropteroate synthase and dihydrofolate reductase mutations may occur during treatment<sup>[12,13]</sup>. One of the important limiting factors in the use of TMP-SMZ is its side effects. As per the findings from a retrospective cohort study, TMP-SMZ treatment was discontinued in 6% of the patients. Within this study group, a total of 67 grade 3 or higher adverse events were reported. Dermatological and hematological side effects were reported as the most common reasons for discontinuation<sup>[14-16]</sup>. Furthermore, therapeutic drug monitoring is recommended during TMP-SMZ therapy. It was reported that the most optimal therapeutic effect with the least amount of side effects can be achieved within the range of 5-8 ng/mL for TMP and 100-200 μg/mL for

SMZ<sup>[15]</sup>. It is important to note, however, that in clinical practice, not every hospital is capable of performing therapeutic drug monitoring.

*P. jirovecii* contains beta-D-glucan in its cell wall<sup>[1,3,17]</sup>. Echinocandins targeting the synthesis of beta-D-glucan seem to be the only effective anti-fungal agents against PCP since ergosterol is absent in the cell wall<sup>[1,3,18]</sup>. Caspofungin was found to be effective in the treatment of PCP in experimental animal models when used alone or in combination with low-dose TMP-SMZ<sup>[7,8]</sup>. It affected the clearance of *Pneumocystis jirovecii*, reducing the cyst burden in lung tissue and ultimately prolonging the survival of HIV-infected mice<sup>[8,9,19]</sup>. TMP-SMZ primarily targets the trophic forms of *Pneumocystis*, whereas caspofungin is effective against the cystic forms, which are significant in the transmission process<sup>[9]</sup>. Prophylactic efficacy was also demonstrated in animal models<sup>[20,21]</sup>.

Caspofungin was used to treat severe or refractory cases of PCP<sup>[22-26]</sup>. In addition, successful results were reported in four cases of PCP in solid organ transplant recipients who received a combination of caspofungin and TMP-SMZ<sup>[27]</sup>. The study conducted by Tiran et al. reported that patients receiving a combination of caspofungin and TMP-SMZ had a better response rate (59.44% vs. 37.78%,  $p < 0.001$ ) and lower in-hospital mortality (24.48% vs. 42.22%,  $p = 0.003$ ) than the patients receiving only TMP-SMZ. Caspofungin combined with TMP-SMZ was reported to be a promising treatment for people living with HIV diagnosed with moderate or severe PCP<sup>[26]</sup>. However, a multicenter observational prospective study conducted by Huang et al. found no statistically significant difference in survival between TMP-SMZ monotherapy, TMP-SMZ plus clindamycin, and TMP-SMZ plus caspofungin groups<sup>[28]</sup>.

Clindamycin combined with primaquine acts against *P. jirovecii*, but the mechanism is not clear<sup>[6]</sup>. The literature reports a limited number of *Pneumocystis* pneumonia (PCP) cases treated with the combination of caspofungin and clindamycin (Table 1)<sup>[6,29,30]</sup>. For instance, Zhao et al. reported the case of a 46-year-old male patient diagnosed with PCP, who was started

on a caspofungin-clindamycin combination due to a history of skin rash, oral ulcers, and severe pancytopenia following the use of TMP-SMZ 10 years earlier. On the thirteenth day of treatment, the caspofungin and clindamycin combination was discontinued due to deterioration of the patient's respiratory function and worsening chest radiography. TMP-SMZ treatment was initiated following a desensitization protocol. On the second day of TMP-SMZ treatment, respiratory functions improved, and the patient was weaned from noninvasive mechanical ventilation on the fourth day. The authors suggested that the failure of the caspofungin-clindamycin combination may have been due to the slower and less effective action of caspofungin on trophic forms of *Pneumocystis* compared to its more effective action on cyst forms<sup>[30]</sup>. Yang et al. reported successful treatment of PCP pneumonia in a patient who had been on long-term immunosuppressive therapy for systemic lupus erythematosus (SLE) using a combination of caspofungin and clindamycin. The patient refused to take TMP/SMZ due to nausea. It was reported that on the fourth day of treatment, fever returned to normal, and dyspnea and saturation improved significantly<sup>[29]</sup>. Li et al. presented a patient with IgA nephropathy diagnosed with PCP. On the seventh day of TMP-SMZ treatment, the patient developed ulcers and hemorrhage on the left side of the tongue. As a result, the treatment regimen was switched to caspofungin combined with clindamycin for 20 days, and the patient was successfully treated<sup>[6]</sup>.

In the present case, TMP/SMZ therapy was discontinued due to its nephrotoxic effects. The patient was unable to continue TMP/SMZ therapy for secondary prophylaxis due to hematological side effects. Given the unavailability of pentamidine and the restricted usage of primaquine primarily for imported malaria cases in Türkiye, the patient received treatment with a combination of caspofungin and clindamycin. The caspofungin and clindamycin combination appears to be effective for moderate to severe PCP cases, but further studies are warranted to establish a strong level of evidence.



**Table 1. PCP Cases treated with caspofungin combined with clindamycin**

Reference	Age	Gender	Diagnosis	Reason for not using TMP-SMZ	Duration	Clinical Improvement	Prognosis
Li et al. <sup>[6]</sup>	46	M	IgA nephropathy	Ulcers and hemorrhage on the left side of the tongue on the seventh day of TMP-SMZ	21	Yes	Survived
Yang et al. <sup>[29]</sup>	66	F	Systemic lupus erythematosus	Nausea	22	Yes	Survived
Yao et al. <sup>[30]</sup>	46	M	HIV	Severe pancytopenia following the use of TMP-SMZ 10 years ago	13	No deterioration Therapy was switched to TMP-SMZ with a desensitization protocol	Survived
Present case	54	M	HIV	Acute renal failure and pancytopenia	21	Yes	Survived

**CONFLICT of INTEREST**

No conflict of interest declared.

**AUTHORSHIP CONTRIBUTIONS**

Concept and Design: GRY, OK, AÇİ

Analysis/Interpretation: GRY, OK, AÇİ, ENT, OÜ, FZA

Data Collection or Processing: GRY, ENT, OK, OÜ, EŞÇ, BO

Writing: GRY, OK, OÜ

Review and Correction: GRY, OK

Final Approval: All of authors

**REFERENCES**

1. Clinical Info. *Pneumocystis pneumonia. Guidelines for the prevention and treatment of opportunistic infections in adults and adolescents with HIV.* Available from: <https://clinicalinfo.hiv.gov/en/guidelines/hiv-clinical-guidelines-adult-and-adolescent-opportunistic-infections/pneumocystis-0> (Accessed date: 24.08.2022).
2. Helweg-Larsen J, Tsolaki AG, Miller RF, Lundgren B, Wakefield AE. Clusters of *Pneumocystis carinii* pneumonia: Analysis of person-to-person transmission by genotyping. *QJM* 1998;91:813-20. <https://doi.org/10.1093/qjmed/91.12.813>
3. Hughes W, Leoung G, Kramer F, Bozzette SA, Safrin S, Frame P, et al. Comparison of atovaquone (566C80) with trimethoprim-sulfamethoxazole to treat *Pneumocystis carinii* pneumonia in patients with AIDS. *N Engl J Med* 1993;328:1521-7. <https://doi.org/10.1056/NEJM199305273282103>
4. Safrin S, Finkelstein DM, Feinberg J, Frame P, Simpson G, Wu A, et al. Comparison of three regimens for treatment of mild to moderate *Pneumocystis carinii* pneumonia in patients with AIDS. A double-blind, randomized, trial of oral trimethoprim-sulfamethoxazole, dapsone-trimethoprim, and clindamycin-primaquine. ACTG 108 Study Group. *Ann Intern Med* 1996;124:792-802. <https://doi.org/10.7326/0003-4819-124-9-199605010-00003>
5. European AIDS Clinical Society Guidelines. Version 11.0, October 2021. Available from: [https://www.eacsociety.org/media/final2021eacsguidelinesv11.0\\_oct2021.pdf](https://www.eacsociety.org/media/final2021eacsguidelinesv11.0_oct2021.pdf).
6. Li H, Huang H, He H. Successful treatment of severe *Pneumocystis pneumonia* in an immunosuppressed patient using caspofungin combined with clindamycin: A case report and literature review. *Pulmonary Medicine* 2016;16:144. <https://doi.org/10.1186/s12890-016-0307-0>
7. Sun P, Tong Z. Efficacy of caspofungin, a 1,3- $\beta$ -D-glucan synthase inhibitor, on *Pneumocystis carinii* pneumonia in rats. *Med Mycol* 2014;52:798-803. <https://doi.org/10.1093/mmy/myu060>
8. Lobo ML, Esteves F, de Sousa B, Cardoso F, Cushion MT, Antunes F, et al. Therapeutic potential of caspofungin combined with trimethoprim-sulfamethoxazole for *Pneumocystis pneumonia*: A pilot study in mice. *PLoS ONE* 2013;8:e70619. <https://doi.org/10.1371/journal.pone.0070619>
9. Cushion MT, Linke MJ, Ashbaugh A, Sesterhenn T, Collins MS, Lynch K, et al. Echinocandin treatment of pneumocystis pneumonia in rodent models depletes cysts leaving trophic burdens that cannot transmit the infection. *PLoS ONE* 2010;5:e8524. <https://doi.org/10.1371/journal.pone.0008524>
10. Miller RF, Allen E, Copas A, Singer M, Edwards SG. Improved survival for HIV infected patients with severe *Pneumocystis jirovecii* pneumonia is independent of highly active antiretroviral therapy. *Thorax* 2006;61:716-21. <https://doi.org/10.1136/thx.2005.055905>

11. Fei MW, Kim EJ, Sant CA, Jarlsberg LG, Davis JL, Swartzman A, et al. Predicting mortality from HIV-associated *Pneumocystis pneumonia* at illness presentation: An observational cohort study. *Thorax* 2009;64:1070-6. <https://doi.org/10.1136/thx.2009.117846>
12. Moukhlis R, Boyer J, Lacube P, Bolognini J, Roux P, Hennequin C. Linking *Pneumocystis jirovecii* sulfamethoxazole resistance to the alleles of the DHPS gene using functional complementation in *Saccharomyces cerevisiae*. *Clin Microbiol Infect* 2009;16:501-7. <https://doi.org/10.1111/j.1469-0691.2009.02833.x>
13. Queener SF, Cody V, Pace J, Torkelson P, Gangjee A. Trimethoprim resistance of dihydrofolate reductase variants from clinical isolates of *Pneumocystis jirovecii*. *Antimicrob Agents Chemother* 2013;57:4990-8. <https://doi.org/10.1128/AAC.01161-13>
14. Ice LL, Barreto JN, Dao BD, Wolf RC, Dierkhising RA, Jannetto PJ, et al. Relationship of sulfamethoxazole therapeutic drug monitoring to clinical efficacy and toxicity: A retrospective cohort study. *Therapeutic Drug Monitoring* 2016;38:319-26. <https://doi.org/10.1097/FTD.0000000000000282>
15. Maschmeyer G, Helweg-Larsen J, Pagano L, Robin C, Cordonnier C, Schellongowski P, et al. ECIL guidelines for treatment of *Pneumocystis jirovecii* pneumonia in non-HIV-infected haematology patients. *J Antimicrob Chemother* 2016;71:2405-13. <https://doi.org/10.1093/jac/dkw158>
16. Helweg-Larsen J, Benfield T, Atzori C, Miller RF. Clinical efficacy of first- and second-line treatments for HIV-associated *Pneumocystis jirovecii* pneumonia: A tricentre cohort study. *J Antimicrob Chemother* 2009;64:1282-90. <https://doi.org/10.1093/jac/dkp372>
17. Kottom TJ, Limper AH. Cell wall assembly by *Pneumocystis carinii*. Evidence for a unique *gsc-1* subunit mediating beta-1,3-glucan deposition. *J Biol Chem* 2000;275:40628-34. <https://doi.org/10.1074/jbc.M002103200>
18. De Stefano JA, Myers JD, Du Pont D, Foy JM, Theus SA, Walzer PD, et al. Cell wall antigens of *Pneumocystis carinii* trophozoites and cysts: Purification and carbohydrate analysis of these glycoproteins. *J Eukaryot Microbiol* 1998;45:334-43. <https://doi.org/10.1111/j.1550-7408.1998.tb04545.x>
19. Cushion MT, Collins MS. Susceptibility of *Pneumocystis* to echinocandins in suspension and biofilm cultures. *Antimicrob Agents Chemother* 2011;55:4513-8. <https://doi.org/10.1128/AAC.00017-11>
20. Powles MA, Liberator P, Anderson J, Karkhanis Y, Dropinski JF, Bouffard FA, et al. Efficacy of MK-991 (L-743,872), a semisynthetic pneumocandin, in murine models of *Pneumocystis carinii*. *Antimicrob Agents Chemother* 1998;42:1985-9. <https://doi.org/10.1128/AAC.42.8.1985>
21. Bartizal K, Gill CJ, Abruzzo GK, Flattery AM, Kong L, Scott PM, et al. In vitro preclinical evaluation studies with the echinocandin antifungal MK-0991 (L-743,872). *Antimicrob Agents Chemother* 1997;41:2326-32. <https://doi.org/10.1128/AAC.41.11.2326>
22. Annaloro C, Della Volpe A, Usardi P, Lambertenghi Deliliers G. Caspofungin treatment of *Pneumocystis pneumonia* during conditioning for bone marrow transplantation. *Eur J Clin Microbiol Infect Dis*. 2006;25:52-4. <https://doi.org/10.1007/s10096-005-0065-z>
23. Hof H, Schnulle P. *Pneumocystis jirovecii* pneumonia in a patient with Wegener's granulomatosis treated efficiently with caspofungin. *Mycoses* 2008;51:65-7. <https://doi.org/10.1111/j.1439-0507.2008.01530.x>
24. Darius AJ, Stebbing J, John L, Murungi A, Bower M, Gazzard B, et al. A trial of caspofungin salvage treatment in PCP pneumonia. *Thorax* 2011;66:537-8. <https://doi.org/10.1136/thx.2010.135350>
25. Waters L, Nelson M. The use of caspofungin in HIV-infected individuals. *Expert Opin Investig Drugs* 2007;16:899-908. <https://doi.org/10.1517/13543784.16.6.899>
26. Tian Q, Si J, Jiang F, Xu R, Wei B, Huang B, et al. Caspofungin combined with TMP/SMZ as a first-line therapy for moderate-to-severe PCP in patients with human immunodeficiency virus infection. *HIV Medicine* 2021;22:307-13. <https://doi.org/10.1111/hiv.13013>
27. Utili R, Durante-Mangoni E, Basilico C, Mattei A, Ragone E, Grossi P. Efficacy of caspofungin addition to trimethoprim-sulfamethoxazole treatment for severe *Pneumocystis pneumonia* in solid organ transplant recipients. *Transplantation* 2007;84:685-8. <https://doi.org/10.1097/01.tp.0000280546.91617.6c>
28. Huang Y, He X, Chen H, Harypursat V, Lu Y, Yuan J. No statistically apparent difference in antifungal effectiveness observed among trimethoprim/sulfamethoxazole plus clindamycin or caspofungin, and trimethoprim/sulfamethoxazole monotherapy in HIV-infected patients with moderate to severe *pneumocystis pneumonia*: Results of an observational multicenter cohort study. *Infect Dis Ther* 2022;11:543-57. <https://doi.org/10.1007/s40121-021-00586-5>
29. Yang D, Xu Y, Hong L, Song Z, Ge W. Efficacy of caspofungin combined with clindamycin for *Pneumocystis jirovecii* pneumonia in a systemic lupus erythematosus patient: A case report and literature review. *Respiratory Medicine Case Reports* 2019;26:108-11. <https://doi.org/10.1016/j.rmcr.2018.12.003>
30. Yao Z, Hua Z, Jun X, Chan W, Xiao-jun M. Lack of response in severe *pneumocystis pneumonia* to combined caspofungin and clindamycin treatment: A case report. *Chin Med Sci J* 2011;26:246-8. [https://doi.org/10.1016/S1001-9294\(12\)60009-1](https://doi.org/10.1016/S1001-9294(12)60009-1)

#### Address for Correspondence/Yazışma Adresi

Dr. Gül Ruhsar YILMAZ

Department of Infectious Diseases and  
Clinical Microbiology, Süleyman Demirel University  
Faculty of Medicine  
Isparta, Türkiye  
E-mail: ruhsar6@yahoo.com